



Pharmacology and therapeutics

Efficacy of intradermal radiofrequency combined with autologous platelet-rich plasma in striae distensae: a pilot study

In Su Kim¹, MD, Kui Young Park¹, MD, Beom Joon Kim¹, MD, Myeung Nam Kim¹, MD, Chan Woong Kim², MD, and Sung Eun Kim², MD

¹Departments of Dermatology, Chung-Ang University College of Medicine, Seoul, ²Departments of Emergency Medicine, Chung-Ang University College of Medicine, Seoul, South Korea

Correspondence

Beom Joon Kim, MD
Department of Dermatology
Chung-Ang University Hospital
224-1, Heukseok-dong, Dongjak-ku
Seoul 156-755
South Korea
E-mail: beomjoon@unitel.co.kr

Conflicts of interest: None.

doi: 10.1111/j.1365-4632.2012.05530.x

Abstract

Background Different types of laser have recently been reported as effective tools of treatment in striae distensae. Although fractional photothermolysis is effective for striae distensae, post-inflammatory hyperpigmentation is a major concern and common complication. There are no reports of the effects of using an intradermal radiofrequency (RF) device in striae distensae. Autologous platelet-rich plasma (PRP) is an effective treatment known for its wound-healing effects.

Methods Nineteen Asian female patients with striae distensae were enrolled in this study. Three sessions of intradermal RF (1134-kHz frequency, 12-W power, 26-G electrode size) combined with autologous PRP were performed in each patient at intervals of 4 weeks. Patients were evaluated subjectively by the investigators and by themselves.

Results Evaluation of clinical results at 4 weeks after treatment showed that only one (5.3%) of the 19 patients achieved excellent improvement, whereas seven (36.8%) demonstrated marked improvement, six (31.6%) showed moderate improvement and five (26.3%) showed mild improvement. None of the patients showed worsening of striae distensae. A total of 63.2% of patients reported they were “satisfied” or “very satisfied” with the degree of overall improvement.

Conclusions Intradermal RF combined with autologous PRP appears to be an effective treatment for striae distensae.

Introduction

Striae distensae are dermal scars with flattening and atrophy of the epidermis. They are commonly seen in adolescents and young adults.¹ It has been suggested that the extracellular matrix is altered or damaged by continuous and progressive stretching forces. Part of the difficulty in determining the etiology of striae refers to the variability in the clinical situations in which they arise.² Causes include mechanical stress such as that caused by weight changes or weight training, corticosteroid therapy, Cushing’s syndrome, infections, and hormonal factors resulting from puberty and pregnancy.³

Multiple treatment modalities have been tried with variable results. The treatment of cosmetically distressing stretch marks has been disappointing. There is no widely accepted surgical procedure for improving the appearance of stretch marks. Laser therapy has been advocated as a treatment for striae distensae, as well as for different forms of scar. Some modalities, such as fractional photo-

thermolysis, intensive pulsed light, pulsed dye laser and radiofrequency (RF), have been reported to offer some hope for the improvement of stretch marks.⁴⁻⁶

Recently, an intradermal RF device was developed especially for the injection of a filler. This new device is capable of delivering higher energy fluencies direct to the dermis and passing injection materials through a needle electrode (Fig. 1). This produces heat when the tissue electrical resistance converts the electric current to thermal energy in the dermis, which is responsible for the partial denaturation of pre-existing elastic fibers and collagen bundles.⁷⁻⁹

Hyaluronic acid filler is translucent and makes the skin color brighter at the injection site, which is unsuitable for the treatment of striae distensae. We injected autologous platelet-rich plasma (PRP) in place of filler using the needle electrode of the intradermal RF device as the delivery route. Striae distensae are considered as dermal scars, a status that may stop wound healing. The wound-healing effect of PRP is relatively well known and PRP has been

COLOR




Figure 1 A needle electrode of the intradermal radio-frequency device

used in maxillofacial surgery, tendon and ligament repair, and chronic leg ulcer treatment.¹⁰ The latest application of autologous PRP refers to dermal cosmetic indications. The fact that platelets secrete growth factors and active metabolites means that their applied use can have a positive influence in clinical situations in which rapid healing and tissue regeneration are required.¹⁰

We studied the efficacy of intradermal RF combined with autologous PRP for the treatment of striae distensae in Asian patients. We present the effectiveness and safety

of the treatment of striae distensae with a combination of intradermal RF and autologous PRP.

Materials and methods

Patients

This was a prospective study approved by the local institutional review board and carried out in 19 patients with stretch marks, all of Asian origin (with Fitzpatrick skin type IV). The mean age of the patients was 29.9 years (range: 19–43 years). None of the patients had a history of treatment for stretch marks. The mean duration of striae was 9.7 years (range: 5–22 years). Causes of striae included weight training (two patients), weight gain (13 patients) and pregnancy (four patients). All patients were informed of the nature of the treatment and provided informed consent. They received three sessions of treatment administered at 4-week intervals. Table 1 details the subject characteristics. Patients were excluded if they had a history of keloids, collagen or elastin disorders, usage of topical or oral retinoids, or were pregnant or immunosuppressed.

Treatment

All participants were treated with three sessions of intradermal RF combined with autologous PRP, once every 4 weeks. Topical anesthetic cream (EMLA™; AstraZeneca LP, Wilmington, DE, USA) was applied 30 min before each treatment. The intradermal RF device (SpheroFill™; Promoltalia Inc., Naples, Italy) was used with a frequency of 1134 kHz,

Table 1 Baseline characteristics of patients and clinical outcomes after intradermal radiofrequency combined with autologous platelet-rich plasma

Patient no.	Age, years	Site	Duration of striae, years	Clinical improvement ^a	Patient satisfaction
1	19	Thighs and buttocks, both	5	Moderate	Satisfied
2	43	Thighs and calves, both	22	Mild	Slightly satisfied
3	21	Axillae, both	5	Excellent	Very satisfied
4	34	Thighs, both	15	Marked	Satisfied
5	32	Thighs, both	9	Marked	Satisfied
6	26	Axillae, both	8	Marked	Satisfied
7	24	Calves, both	8	Moderate	Slightly satisfied
8	27	Abdomen	10	Marked	Very satisfied
9	27	Popliteal areas, both	7	Mild	Unsatisfied
10	22	Thighs and popliteal areas, both	5	Marked	Satisfied
11	26	Calves, both	7	Mild	Satisfied
12	23	Thighs and buttocks, both	6	Marked	Very satisfied
13	35	Calves, both	7	Mild	Unsatisfied
14	31	Thighs and calves, both	8	Marked	Satisfied
15	37	Abdomen	12	Moderate	Slightly satisfied
16	42	Thighs and buttocks, both	19	Mild	Satisfied
17	33	Axillae and popliteal areas, both	12	Moderate	Satisfied
18	37	Axillae, both	11	Mild	Slightly satisfied
19	29	Thighs and buttocks, both	9	Moderate	Slightly satisfied

^aNo change, 0%; mild, 0–25%; moderate, 25–50%; marked, 50–75%; excellent, 75–100%.

power of 12 W and electrode size of 26 G. This is a bipolar electric wave generator that can emit at two different frequencies (1134 and 1769 kHz) within the range of AM broadcasting radio waves (525–1775 kHz). Bipolar RF is emitted through a needle electrode.

Platelet-rich plasma was produced using a commercially available system (MyCells[®]; Estar Technologies Ltd, Holon,

Israel) consisting of two vacuum tubes with acid-citrate-dextrose (ACD) anticoagulant and a separating gel, and filter sleeves that filter impurities from the PRP. The procedure for preparation of the PRP included various phases: centrifugation at 1200 g (4000 rpm) for 7 min; discarding of platelet-poor plasma; resuspension of platelets in a small volume (4 ml) of plasma; PRP filtering using the sleeve filter, and transfer into a needle electrode. This needle electrode was used to deliver the PRP into the dermis at the site of striae distensae.

Objective and subjective evaluations

All patients were photographed immediately before each session and 4 weeks after the third treatment. Patients were evaluated subjectively by the investigators as well as by self-evaluation. Clinical improvement was analyzed according to the evaluation of the photographic material by two dermatologists blinded to the study group. Evaluators used a quartile grading scale of 0 (no change, 0%), 1 (mild improvement, 0–25%), 2 (moderate improvement, 25–50%), 3 (marked improvement, 50–75%) and 4 (excellent improvement, 75–100%). In addition, each participant was asked to rate her overall satisfaction with the treatment 4 weeks after it was completed according to

whether she was “unsatisfied”, “slightly satisfied”, “satisfied” or “very satisfied”. Patients were also asked to report on any side-effects of the treatment, including bleeding, oozing, post-treatment dyschromia, crust and severe erythema.

Results

Four weeks after the final treatment, the two dermatologists blinded to the study group evaluated the photographs and found that one of the 19 patients (5.3%) showed excellent improvement in striae (Fig. 2, Table 1) and seven (36.8%) showed marked improvement. Six (31.6%) patients showed moderate improvement (Fig. 3) and five (26.3%) demonstrated minimal improvement (Fig. 4). None of the patients showed worsening of the striae distensae (Fig. 5). On the quartile grading scale, the mean clinical improvement at 4 weeks after the final treatment was 2.3. There were no significant differences according to anatomic site. An evaluation of overall participant satisfaction after the treatment revealed that three of the 19 participants (15.8%) were very satisfied, nine (47.4%) were satisfied, five (26.3%) were slightly satisfied and two (10.5%) were unsatisfied (Fig. 6). Patient satisfaction grades almost paralleled levels of clinical improvement.

Overall, the treatment was well tolerated. The patients described the procedure as mildly to moderately uncomfortable. Overall, 21% of subjects experienced transient bruising. There were no significant side-effects other than

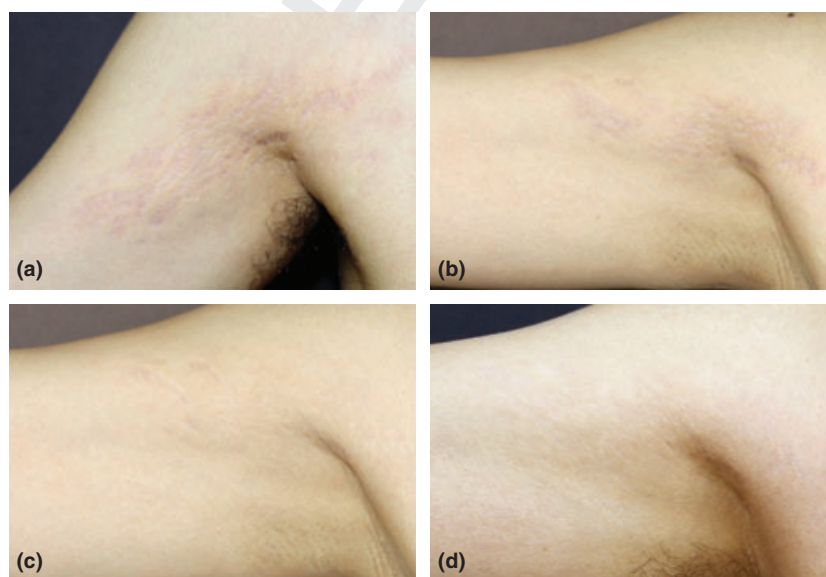


Figure 2 Patient 3. Striae distensae on the right axilla in a 21-year-old woman at (a) baseline and (b–d) 4 weeks after the first, second and third treatments with intradermal radiofrequency combined with autologous platelet-rich plasma, respectively. Note the near-total improvement

COLOR

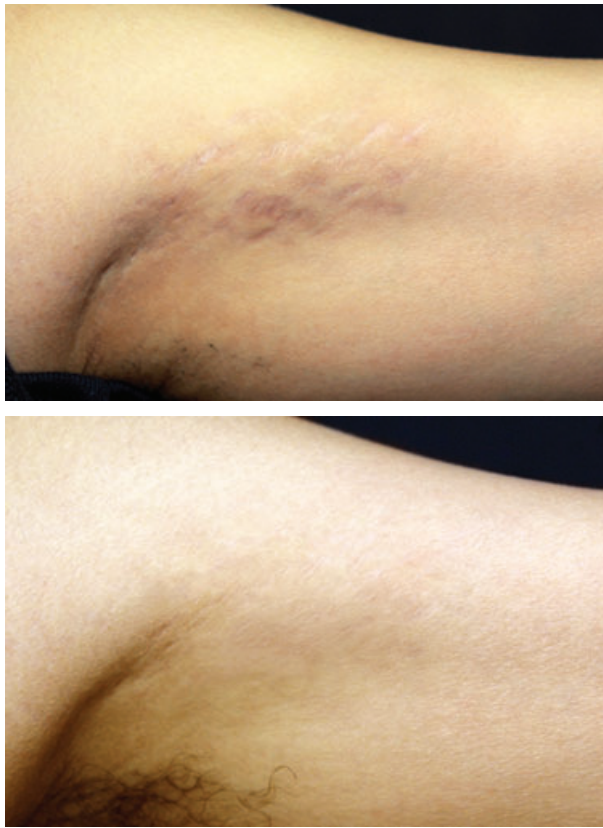

Figure 3 Patient 17. Striae distensae on the left axilla in a 33-year-old woman at (a) baseline and (b) 4 weeks after the third treatment with intradermal radiofrequency combined with autologous platelet-rich plasma. Note the moderate improvement

transient bruising. Post-treatment bruising, lasting 3–7 d, was observed in all patients, whereas post-inflammatory hyperpigmentation (PIH) was not observed in any patient. Other potential adverse events such as burns, bullae formation, and severe and persistent hyperpigmentation were not observed.

Discussion

The treatment of striae distensae remains challenging. The therapeutic options for striae distensae are numerous and include the use of topical tretinoin,^{2,11,12} microdermabrasion,^{4,13} intense pulsed light,⁵ and various lasers such as the 585-nm pulsed dye laser,⁶ copper bromide laser,¹⁴ fractional photothermolysis^{15,16} and 308-nm excimer laser.¹⁷ Topical 0.1% tretinoin cream was found to improve the clinical appearance of early erythematous stretch marks.¹¹ However, another double-blind, placebo-controlled study found that 0.025% tretinoin cream was not effective in the treatment of striae rubra and

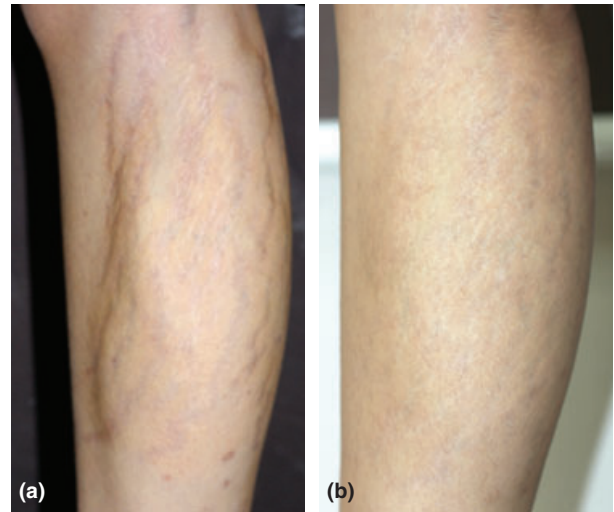


Figure 4 Patient 11. Striae distensae on the right calf of a 26-year-old woman (a) before and (b) 4 weeks after the third treatment with intradermal radiofrequency combined with autologous platelet-rich plasma. Note the minimal improvement

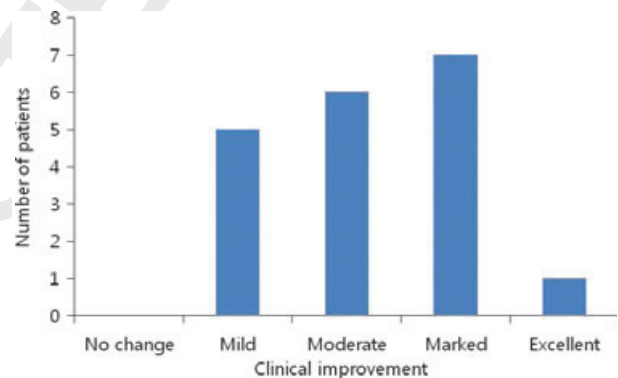


Figure 5 Grade of clinical improvement after three sessions of treatment with intradermal radiofrequency combined with autologous platelet-rich plasma

alba.¹² One study showed intense pulsed light to improve striae alba, but PIH occurred in 40% of the patient group.⁵ The 585-nm pulsed dye laser may help to improve striae rubra, but had no effect on striae alba.¹⁸ Moreover, PIH is a significant side-effect after treatment with the pulsed dye laser in Fitzpatrick skin types IV–VI as melanin acts as a competing chromophore with hemoglobin for light energy.^{6,18} The 308-nm excimer laser has been shown to temporarily repigment striae alba by increasing the number of melanocytes, without improving atrophy.¹⁷ These multiple treatments have been tried with varying results, but no properly adequate remedy has yet been identified.

COLOR

LOW RESOLUTION COLOR FIG

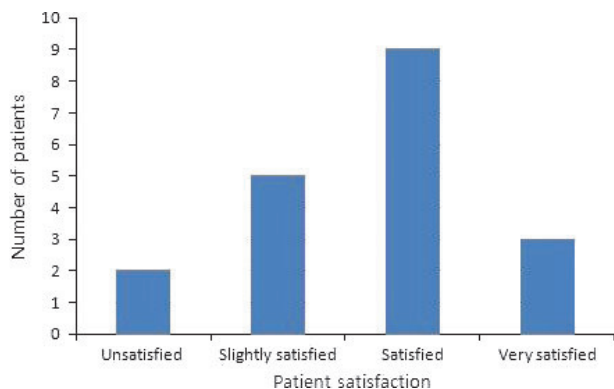


Figure 6 Patient satisfaction levels after three sessions of treatment with intradermal radiofrequency combined with autologous platelet-rich plasma

The intradermal RF device was initially developed for the injection of a filler. This new bipolar RF device is capable of delivering higher energy fluencies direct to the dermis, passing injection materials through a needle electrode. Bipolar RF devices are based on the principle of heat generation that occurs in response to poor electrical conductance according to Ohm's law (heat generation is directly correlated with tissue resistance). The heat that is generated is sufficient to cause thermal damage to the surrounding connective tissue,¹⁹ which is responsible for the partial denaturation of pre-existing elastic fibers and collagen bundles.⁸ Initial collagen denaturation within thermally modified deep tissue is thought to represent the mechanism for immediate tissue contraction; subsequent neocollagenesis further tightens the dermal tissue and reduces striae.²⁰ Alvarez *et al.*²¹ used animal models to reveal interesting results on the effects of RF treatment on dermal cellularity and collagen formation. They found changes in the papillary dermis in the form of an expansion related to edema and vascular congestion.²¹ These changes were followed by an increase in cellularity and an accumulation of intercellular substances. Subsequently, increases in collagen, elastic fibers and mucopolysaccharides were observed.²¹ These changes led to increased dermal thickness and collagen content.²¹ Zelickson *et al.*²² suggested that collagen fibril contraction occurs immediately after RF treatment and gives rise to tissue contraction and thermally mediated wound healing, which induces new collagen production.

Autologous PRP is the plasma portion of autologously sourced blood with an iatrogenically high platelet concentration.²³ At sites of tissue damage, platelets are the first cells to arrive and play an important role in mediating tissue repair through the release of growth factors from their α -granules.²³ Platelet-derived factors can influence cellular growth, morphogenesis and differentiation

that can be used therapeutically to accelerate natural healing processes.¹⁰ Platelet-rich plasma has these wound-healing properties, affecting endothelial cells, erythrocytes and collagen,¹⁰ which potentially aids in the healing of the localized chronic inflammation believed to be a factor in the etiology of striae distensae. Furthermore, because thermal damage from intradermal RF has characteristics similar to those of many wounds, we thought that combination treatment with intradermal RF and autologous PRP would accelerate recovery and reduce adverse events such as erythema or edema. In addition, this combination protocol may eventuate in enhanced localized collagen neogenesis and redistribution.

In this study, we used three sessions of intradermal RF combined with autologous PRP administered once every 4 weeks. All of our participants showed satisfactory changes. On the quartile grading scale, the mean clinical improvement at 4 weeks after the final treatment was 2.3, corresponding to moderate improvement. A total of 42.1% of participants demonstrated excellent or marked improvement. No patient was reported to show no improvement. In self-evaluations, 63.2% of patients described themselves as "satisfied" or "very satisfied" with their overall improvement.

A combination of RF and autologous PRP might have synergistic benefits in effectiveness and cause fewer adverse events. In this study, we did not compare the effects of intradermal RF or autologous PRP alone with those of the intradermal RF and autologous PRP combination. Further controlled studies will be required to address such comparisons. Additionally, the optimization of treatment protocols and confirmation of the efficacy of treatment should be established by clinical trials involving larger numbers of patients.

References

- 1 Tay YK, Kwok C, Tan E. Non-ablative 1450-nm diode laser treatment of striae distensae. *Lasers Surg Med* 2006; 38: 196-199.
- 2 Elson ML. Treatment of striae distensae with topical tretinoin. *J Dermatol Surg Oncol* 1990; 16: 267-270.
- 3 Nigam PK. Striae cutis distensae. *Int J Dermatol* 1989; 28: 426-428.
- 4 Lee SE, Kim JH, Lee SJ, *et al.* Treatment of striae distensae using an ablative 10,600-nm carbon dioxide fractional laser: a retrospective review of 27 participants. *Dermatol Surg* 2010; 36: 1683-1690.
- 5 Hernández-Pérez E, Colombo-Charrier E, Valencia-Ibieta E. Intense pulsed light in the treatment of striae distensae. *Dermatol Surg* 2002; 28: 1124-1130.
- 6 Suh DH, Chang KY, Son HC, *et al.* Radiofrequency and 585-nm pulsed dye laser treatment of striae distensae: a

- report of 37 Asian patients. *Dermatol Surg* 2007; 33: 29–34.
- 7 Ruiz-Esparza J, Gomez JB. The medical face lift: a non-invasive, non-surgical approach to tissue tightening in facial skin using non-ablative radiofrequency. *Dermatol Surg* 2003; 29: 325–332.
- 8 Fitzpatrick R, Geronemus R, Goldberg D, et al. Multicenter study of non-invasive radiofrequency for periorbital tissue tightening. *Lasers Surg Med* 2003; 33: 232–242.
- 9 Hsu TS, Kaminer MS. The use of non-ablative radiofrequency technology to tighten the lower face and neck. *Semin Cutan Med Surg* 2003; 22: 115–123.
- 10 Anitua E, Andia I, Ardanza B, et al. Autologous platelets as a source of proteins for healing and tissue regeneration. *Thromb Haemost* 2004; 91: 4–15.
- 11 Kang S, Kim KJ, Griffiths CE, et al. Topical tretinoin (retinoic acid) improves early stretch marks. *Arch Dermatol* 1996; 132: 519–526.
- 12 Pribanich S, Simpson FG, Held B, et al. Low-dose tretinoin does not improve striae distensae: a double-blind, placebo-controlled study. *Cutis* 1994; 54: 121–124.
- 13 McDaniel DH. Laser therapy of stretch marks. *Dermatol Clin* 2002; 20: 67–76.
- 14 Longo L, Postiglione MG, Marangoni O, et al. Two-year follow-up results of copper bromide laser treatment of striae. *J Clin Laser Med Surg* 2003; 21: 157–160.
- 15 Kim BJ, Lee DH, Kim MN, et al. Fractional photothermolysis for the treatment of striae distensae in Asian skin. *Am J Clin Dermatol* 2008; 9: 33–37.
- 16 Bak H, Kim BJ, Lee WJ, et al. Treatment of striae distensae with fractional photothermolysis. *Dermatol Surg* 2009; 35: 1215–1220.
- 17 Goldberg DJ, Sarradet D, Hussain M. 308-nm excimer laser treatment of mature hypopigmented striae. *Dermatol Surg* 2003; 29: 596–598.
- 18 Jimenez GP, Flores F, Berman B, et al. Treatment of striae rubra and striae alba with the 585-nm pulsed-dye laser. *Dermatol Surg* 2003; 29: 362–365.
- 19 Khan MH, Victor F, Rao B, et al. Treatment of cellulite: Part II. Advances and controversies. *J Am Acad Dermatol* 2010; 62: 373–384.
- 20 Arnoczky SP, Aksan A. Thermal modification of connective tissues: basic science considerations and clinical implications. *J Am Acad Orthop Surg* 2000; 8: 305–313.
- 21 Alvarez N, Ortiz L, Vicente V, et al. The effects of radiofrequency on skin: experimental study. *Lasers Surg Med* 2008; 40: 76–82.
- 22 Zelickson BD, Kist D, Bernstein E, et al. Histological and ultrastructural evaluation of the effects of a radiofrequency-based non-ablative dermal remodeling device: a pilot study. *Arch Dermatol* 2004; 140: 204–209.
- 23 Eppley BL, Pietrzak WS, Blanton M. Platelet-rich plasma: a review of biology and applications in plastic surgery. *Plast Reconstr Surg* 2006; 118: 147–159.

Author Query Form

Journal: IJD

Article: 5530

Dear Author,

During the copy-editing of your paper, the following queries arose. Please respond to these by marking up your proofs with the necessary changes/additions. Please write your answers on the query sheet if there is insufficient space on the page proofs. Please write clearly and follow the conventions shown on the attached corrections sheet. If returning the proof by fax do not write too close to the paper's edge. Please remember that illegible mark-ups may delay publication.

Many thanks for your assistance.

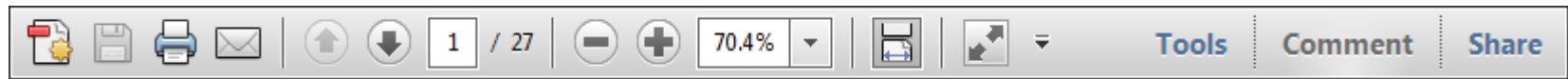
Query reference	Query	Remarks
1	AUTHOR: Please check that authors and their affiliations are correct.	
2	AUTHOR: please check Conflicts of interest statement.	
3	AUTHOR: 'acid-citrate-dextrose' inserted for ACD; please check	
4	AUTHOR: 4000 rpm: please replace this with the correct g value.	
5	AUTHOR: give percentage to one decimal place	
6	AUTHOR: References [10] and [24] are identical. Hence, reference [24] is deleted and rest of the references is renumbered. Please check.	
7	AUTHOR: Figure 5 has been saved at a low resolution of 223 dpi. Please resupply at 600 dpi. Check required artwork specifications at http://authorservices.wiley.com/submit_illust.asp?site=1	
8	AUTHOR: Figure 6 has been saved at a low resolution of 133 dpi. Please resupply at 600 dpi. Check required artwork specifications at http://authorservices.wiley.com/submit_illust.asp?site=1	

USING e-ANNOTATION TOOLS FOR ELECTRONIC PROOF CORRECTION

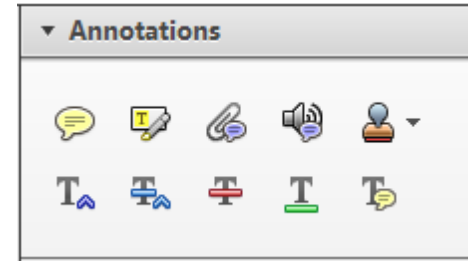
Required software to e-Annotate PDFs: Adobe Acrobat Professional or Adobe Reader (version 8.0 or above). (Note that this document uses screenshots from Adobe Reader X)

The latest version of Acrobat Reader can be downloaded for free at: <http://get.adobe.com/reader/>

Once you have Acrobat Reader open on your computer, click on the [Comment](#) tab at the right of the toolbar:



This will open up a panel down the right side of the document. The majority of tools you will use for annotating your proof will be in the [Annotations](#) section, pictured opposite. We've picked out some of these tools below:



1. Replace (Ins) Tool – for replacing text.

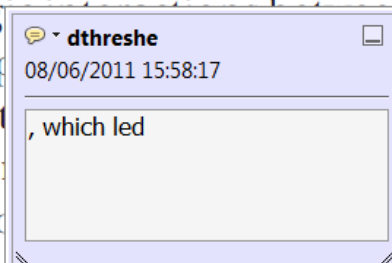


Strikes a line through text and opens up a text box where replacement text can be entered.

How to use it

- Highlight a word or sentence.
- Click on the [Replace \(Ins\)](#) icon in the Annotations section.
- Type the replacement text into the blue box that appears.

standard framework for the analysis of microeconomics. Nevertheless, it also led to the emergence of strategic behavior in the number of competitors in the industry. This is that the structure of the industry, which led to the emergence of imperfect competition. The main components of the industry, which are exogenous to the industry, are important works on entry by Shirasaka (henceforth) we open the 'black b



2. Strikethrough (Del) Tool – for deleting text.



Strikes a red line through text that is to be deleted.

How to use it

- Highlight a word or sentence.
- Click on the [Strikethrough \(Del\)](#) icon in the Annotations section.

there is no room for extra profits and the number of competitors are zero and the number of competitors (net) values are not determined by the number of firms. Blanchard and ~~Kiyotaki~~ (1987), in their paper on perfect competition in general equilibrium, discuss the effects of aggregate demand and supply shocks in a classical framework assuming monopolistic competition. An exogenous number of firms

3. Add note to text Tool – for highlighting a section to be changed to bold or italic.



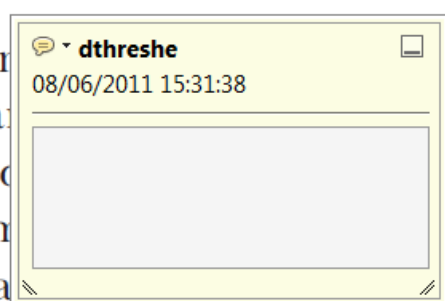Highlights text in yellow and opens up a text box where comments can be entered.

How to use it

- Highlight the relevant section of text.
- Click on the [Add note to text](#) icon in the Annotations section.
- Type instruction on what should be changed regarding the text into the yellow box that appears.

dynamic responses of mark-ups consistent with the VAR evidence

standard framework for the analysis of microeconomics. Nevertheless, it also led to the emergence of strategic behavior in the number of competitors in the industry. This is that the structure of the industry, which led to the emergence of imperfect competition. The main components of the industry, which are exogenous to the industry, are important works on entry by Shirasaka (henceforth) we open the 'black b



4. Add sticky note Tool – for making notes at specific points in the text.

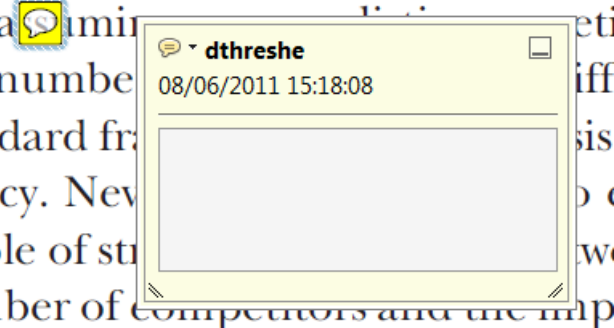


Marks a point in the proof where a comment needs to be highlighted.

How to use it

- Click on the [Add sticky note](#) icon in the Annotations section.
- Click at the point in the proof where the comment should be inserted.
- Type the comment into the yellow box that appears.

standard framework for the analysis of microeconomics. Nevertheless, it also led to the emergence of strategic behavior in the number of competitors in the industry. This is that the structure of the industry, which led to the emergence of imperfect competition. The main components of the industry, which are exogenous to the industry, are important works on entry by Shirasaka (henceforth) we open the 'black b



USING e-ANNOTATION TOOLS FOR ELECTRONIC PROOF CORRECTION

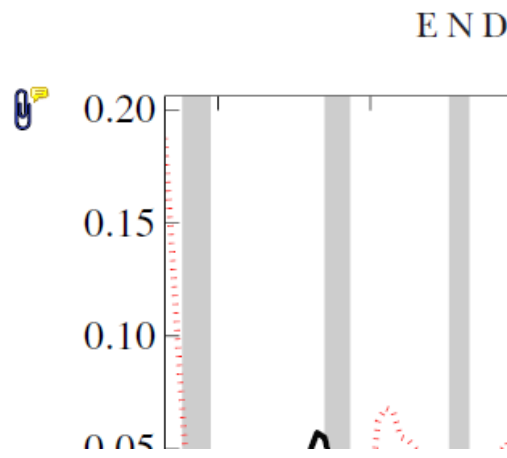
5. Attach File Tool – for inserting large amounts of text or replacement figures.



Inserts an icon linking to the attached file in the appropriate place in the text.

How to use it

- Click on the [Attach File](#) icon in the Annotations section.
- Click on the proof to where you'd like the attached file to be linked.
- Select the file to be attached from your computer or network.
- Select the colour and type of icon that will appear in the proof. Click OK.



6. Add stamp Tool – for approving a proof if no corrections are required.



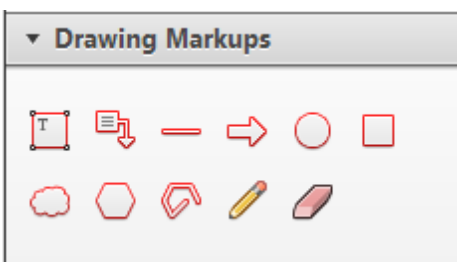
Inserts a selected stamp onto an appropriate place in the proof.

How to use it

- Click on the [Add stamp](#) icon in the Annotations section.
- Select the stamp you want to use. (The [Approved](#) stamp is usually available directly in the menu that appears).
- Click on the proof where you'd like the stamp to appear. (Where a proof is to be approved as it is, this would normally be on the first page).

of the business cycle, starting with the
 on perfect competition, constant ret
 production. In this environment goods
 extra profits and the market for market
 he market for market for market for market
 determined by the model. The New-Key
 otaki (1987), has introduced produc
 general equilibrium models with nomin
 and market for market for market for market

APPROVED

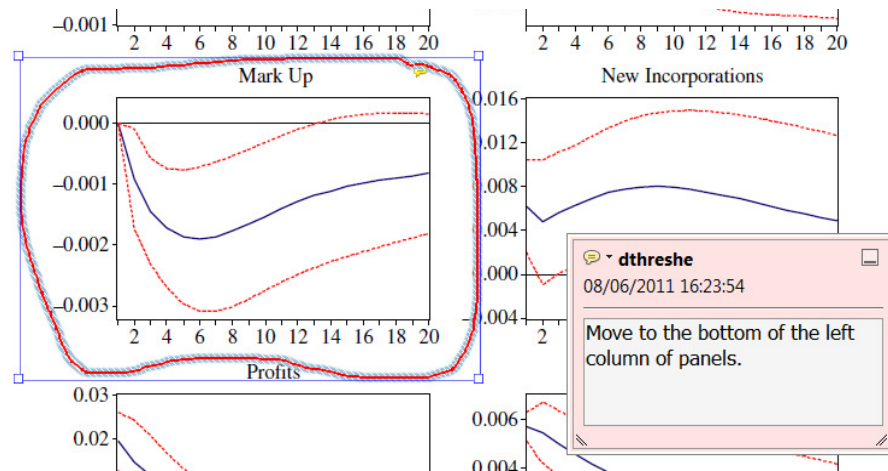


7. Drawing Markups Tools – for drawing shapes, lines and freeform annotations on proofs and commenting on these marks.

Allows shapes, lines and freeform annotations to be drawn on proofs and for comment to be made on these marks..

How to use it

- Click on one of the shapes in the [Drawing Markups](#) section.
- Click on the proof at the relevant point and draw the selected shape with the cursor.
- To add a comment to the drawn shape, move the cursor over the shape until an arrowhead appears.
- Double click on the shape and type any text in the red box that appears.



For further information on how to annotate proofs, click on the [Help](#) menu to reveal a list of further options:

